



PET DOCTORS VETERINARY CLINIC

Canine Report

Patient Name:A. Chua,Channel

Age:0

Sex:Female

Patient ID:2021-10-22-0004

Diagnostic

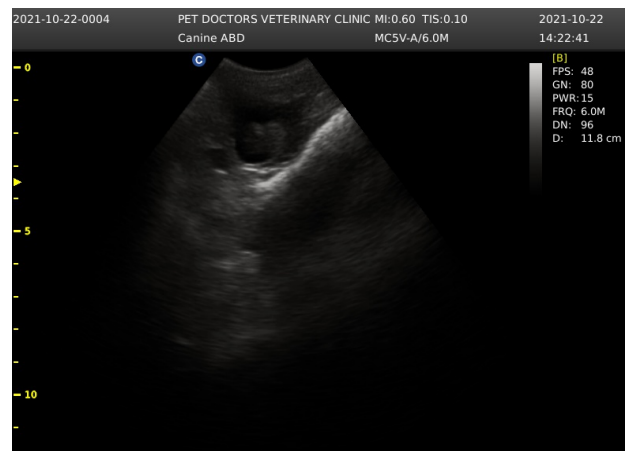
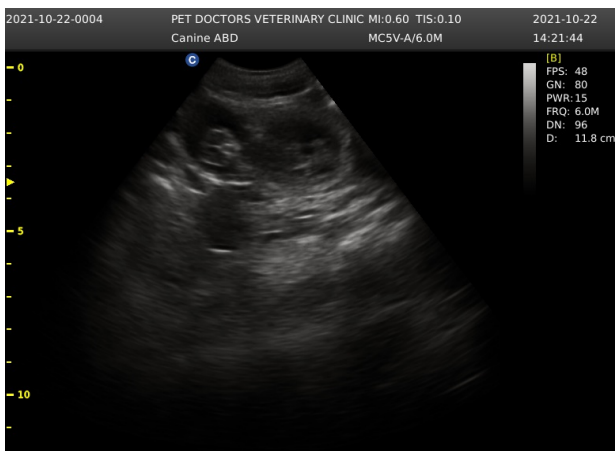
Weight

4.45 kg

BSA

0.27 m²

Ultrasound Image:



Description

Tips

Doctor's signature(or stamp)

Date

This report is used for clinical reference only, Not used as prove material.