



PET DOCTORS VETERINARY CLINIC

Canine Report

Patient Name: Michael Navarro, Brunette

Age: 0

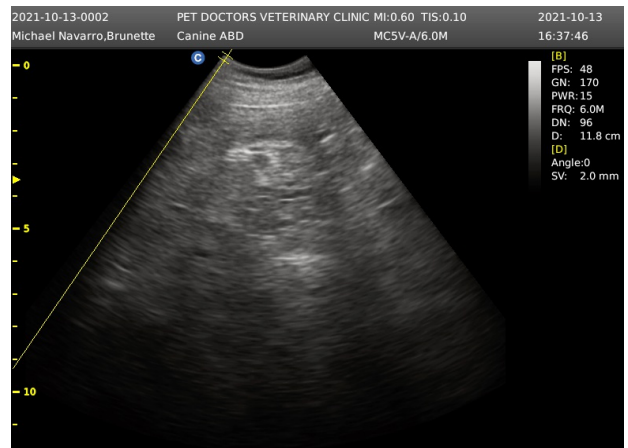
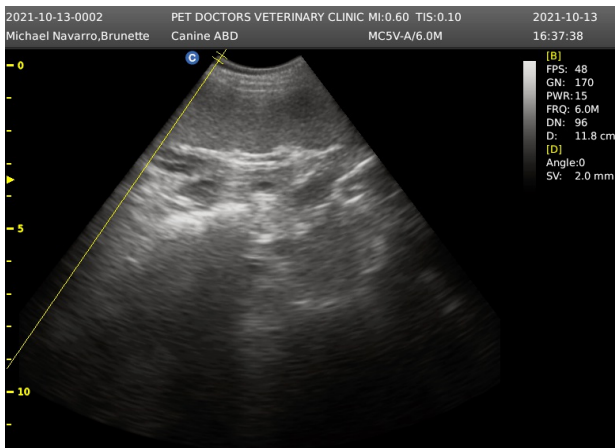
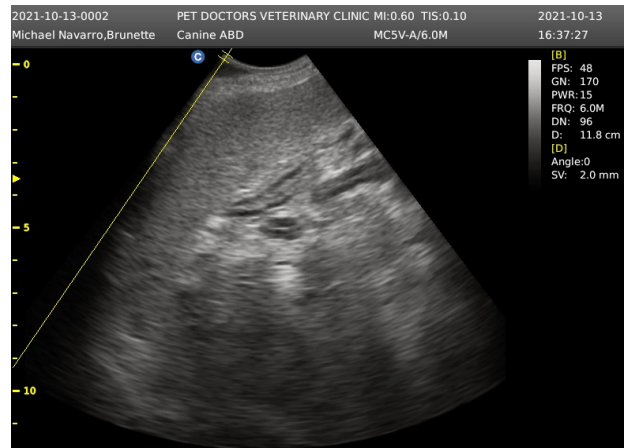
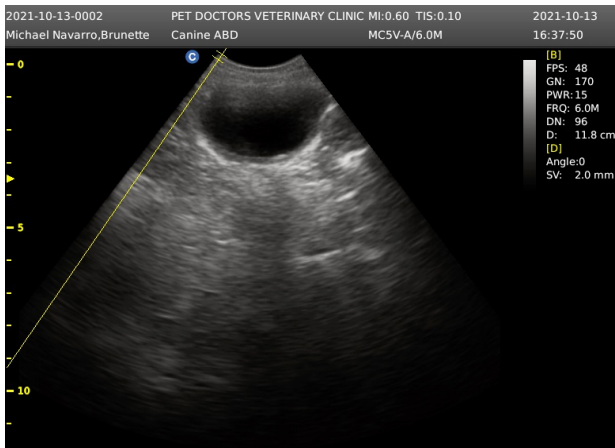
Sex: Female

Patient ID: 2021-10-13-0002

Diagnostic

No fetus/gestational sac seen. Negative pregnancy.

Ultrasound Image:



Description

Tips

Doctor's signature (or stamp)

Date

This report is used for clinical reference only, Not used as prove material.