



# PET DOCTORS VETERINARY CLINIC

## Canine Report

Patient Name: Brenda Garbrillo, Bomi

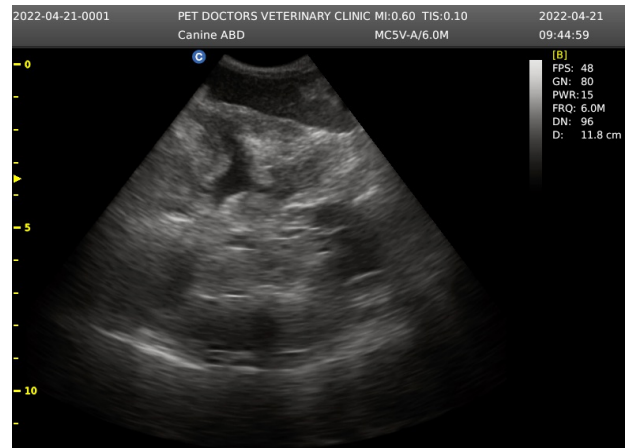
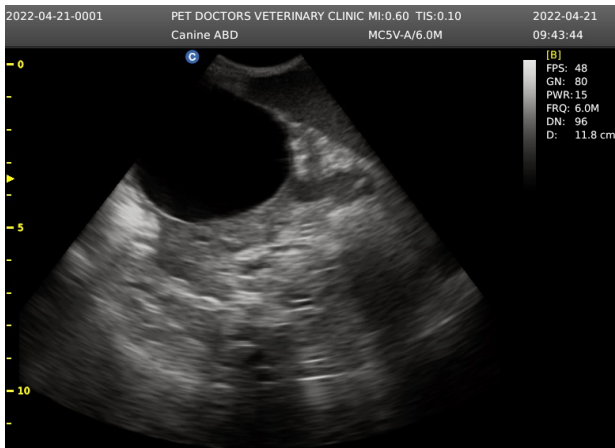
Age: 0

Sex: Female

Patient ID: 2022-04-21-0001

### Diagnostic

### Ultrasound Image:



### Description

No visible gestational sac and/or fetus.

\*to return after 2 weeks for UTZ

### Tips

Doctor's signature(or stamp)

Date

This report is used for clinical reference only, Not used as prove material.