



PET DOCTORS VETERINARY CLINIC

Canine Report

Patient Name: David Palaganas, Willow

Age: 1

Sex: Male

Patient ID: 2022-04-19-0003

Diagnostic

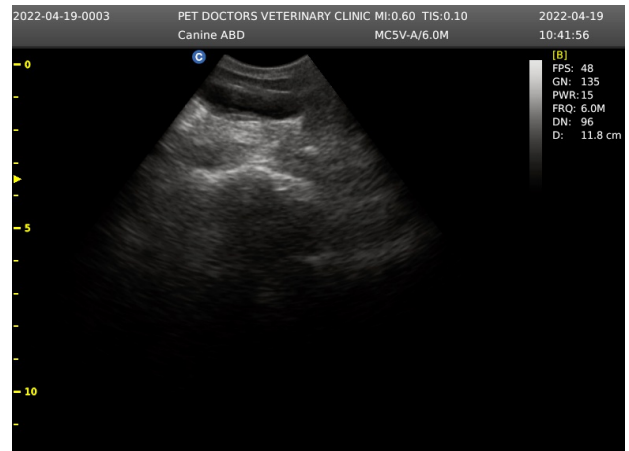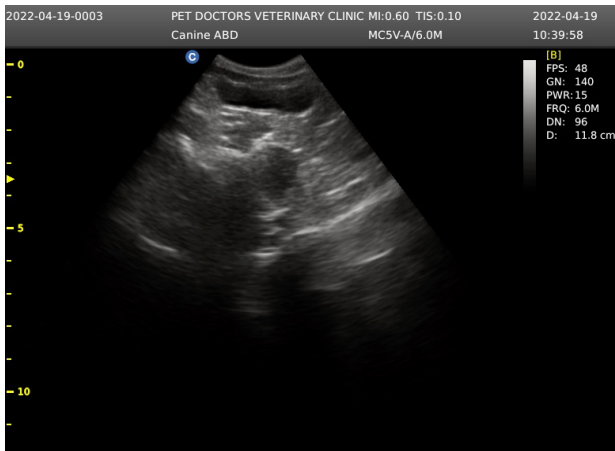
Weight

4.20 kg

BSA

0.27 m²

Ultrasound Image:



Description

Tips

Doctor's signature(or stamp)

Date

This report is used for clinical reference only, Not used as prove material.