



# PET DOCTORS VETERINARY CLINIC

## Canine Report

Patient Name: Catherine Ferrer, Diana

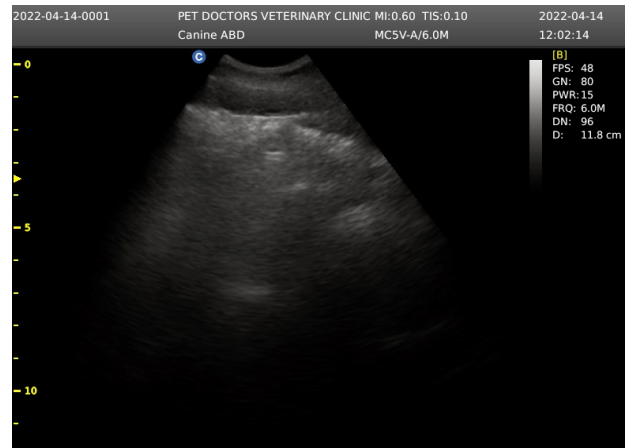
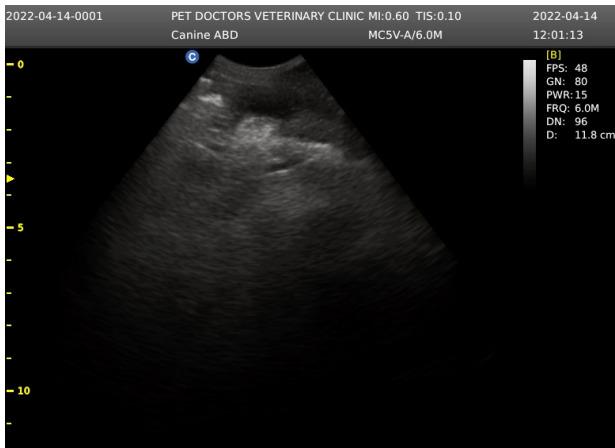
Age: 4

Sex: Female

Patient ID: 2022-04-14-0001

### Diagnostic

### Ultrasound Image:



### Description

### Tips

Doctor's signature(or stamp)

Date

This report is used for clinical reference only, Not used as prove material.