



# PET DOCTORS VETERINARY CLINIC

## Canine Report

Patient Name: Randolph Sanchez, Cembra

Age: 0

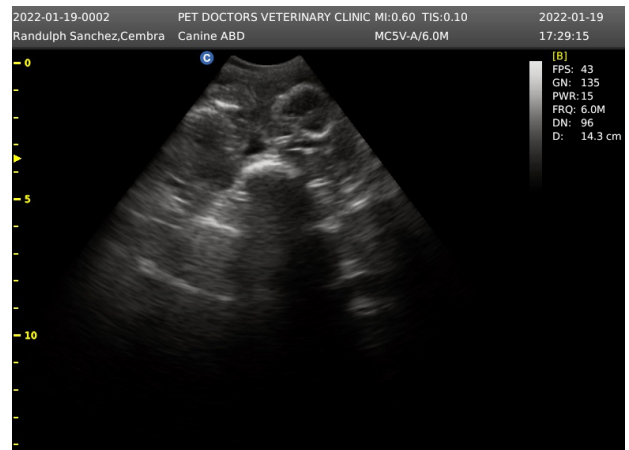
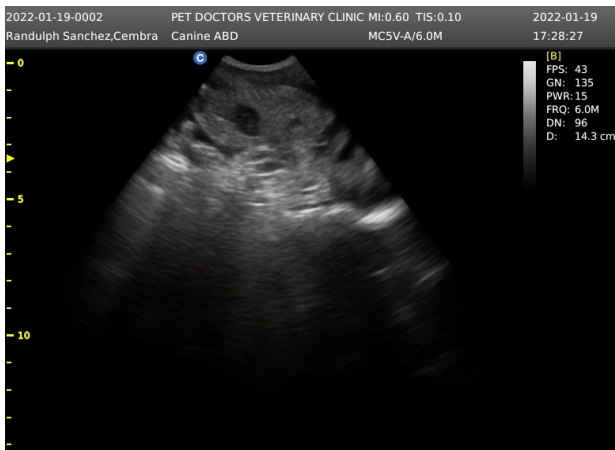
Sex: Female

Patient ID: 2022-01-19-0002

### Diagnostic

HD	2.19 cm Avg	BD_GA	7w1d
HD_GA	7w4d	BD_EDD	2022-02-03
HD_EDD	2022-01-31	Average GA	7w2d
BD	2.91 cm Avg	Average EDD	2022-02-02

### Ultrasound Image:



### Description

### Tips

Doctor's signature(or stamp)

Date

This report is used for clinical reference only, Not used as prove material.