



PET DOCTORS VETERINARY CLINIC

Canine Report

Patient Name: Comelio, Tarra

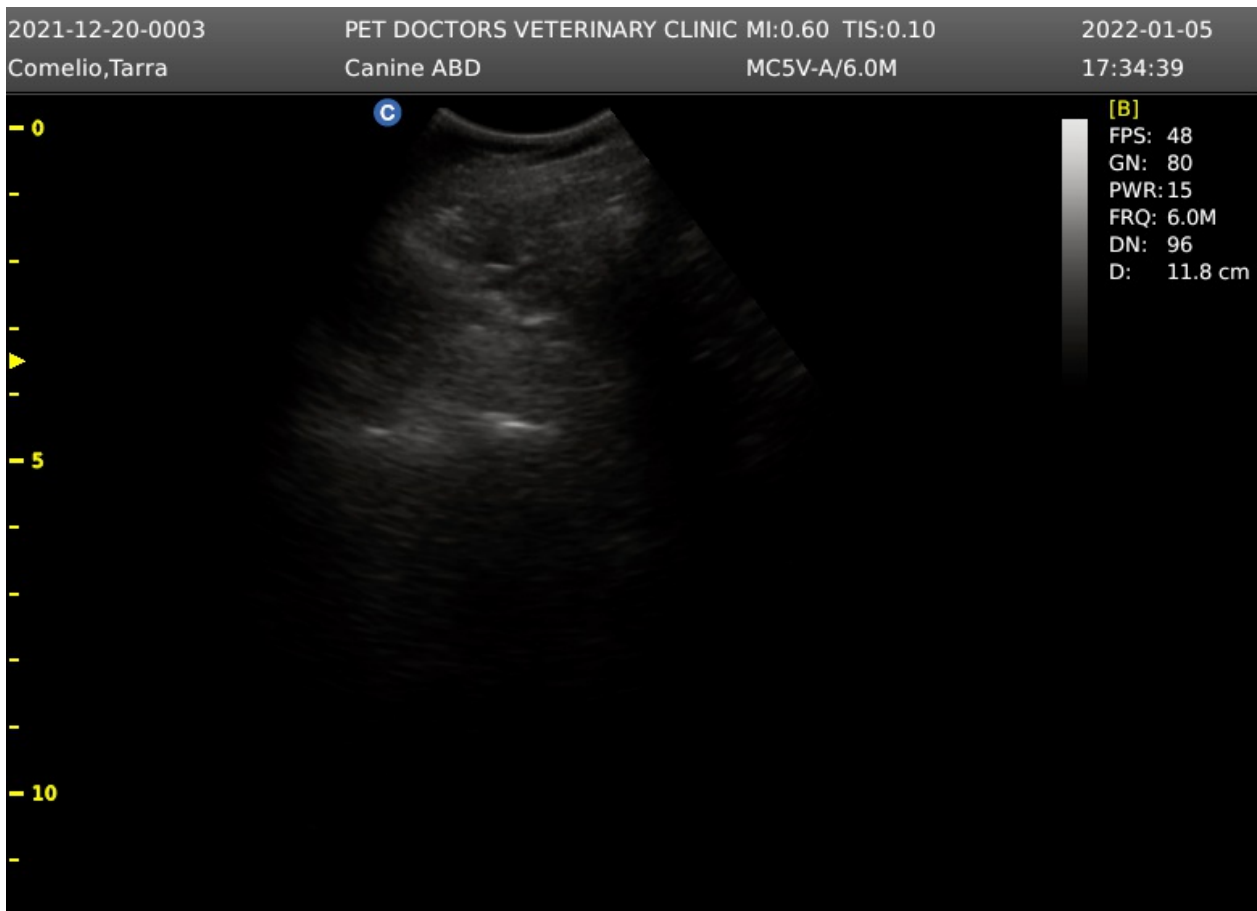
Age: 1

Sex: Female

Patient ID: 2021-12-20-0003

Diagnostic

Ultrasound Image:



Description

No visible fetal sac and/or fetus.

Tips

Doctor's signature(or stamp)

Date

This report is used for clinical reference only, Not used as prove material.