



PET DOCTORS VETERINARY CLINIC

Canine Report

Patient Name: Rosal, HERSHEY

Age: 4

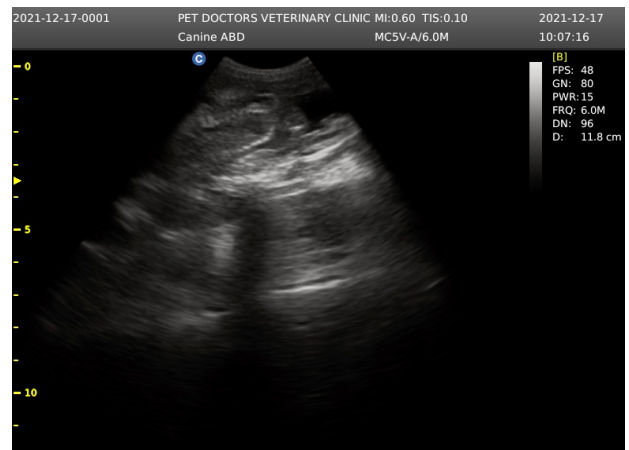
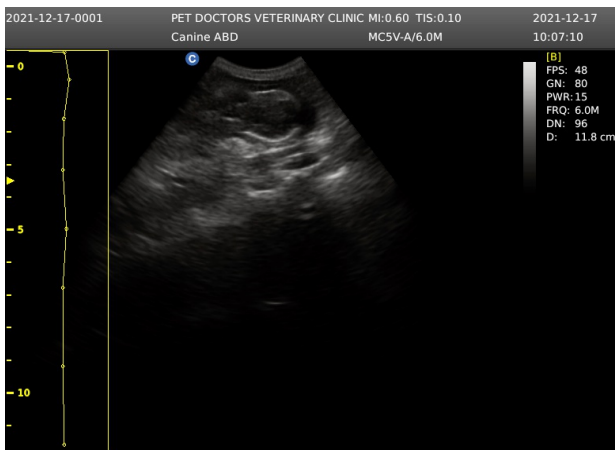
Sex: Female

Patient ID: 2021-12-17-0001

Diagnostic

Weight	5.55 kg	BD	2.53 cm Avg
BSA	0.32 m ²	BD_GA	6w6d
HD	1.62 cm Avg	BD_EDD	2022-01-03
HD_GA	6w2d	Average GA	6w4d
HD_EDD	2022-01-07	Average EDD	2022-01-05

Ultrasound Image:



Description

Tips

Doctor's signature(or stamp)

Date

This report is used for clinical reference only, Not used as prove material.