



PET DOCTORS VETERINARY CLINIC

Canine Report

Patient Name: Vitug, Shiann

Age: 0

Sex: Female

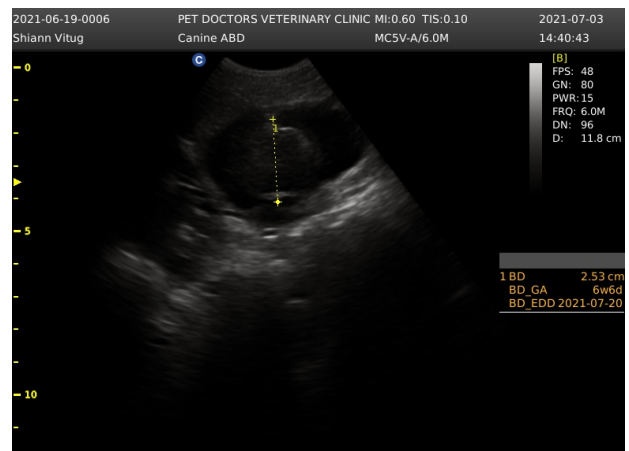
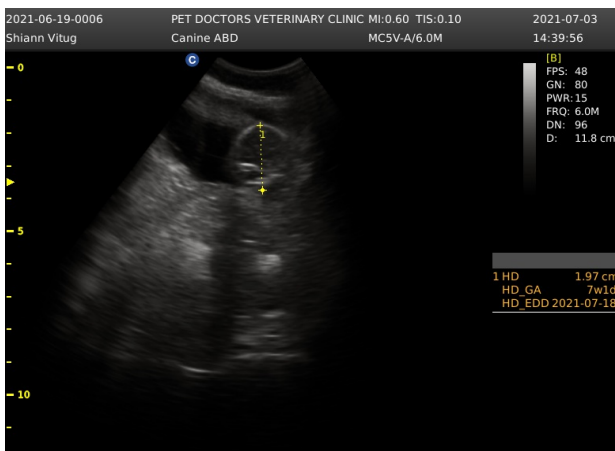
Patient ID: 2021-06-19-0006

Diagnostic

HD 3.33 cm Avg

BD 11.18 cm Avg

Ultrasound Image:



Description

Tips

Doctor's signature(or stamp)

Date

This report is used for clinical reference only, Not used as prove material.