



PET DOCTORS VETERINARY CLINIC

Canine Report

Patient Name:Domingo Cruz,BELLA

Age:2

Sex:Female

Patient ID:2021-05-25-0002

Diagnostic

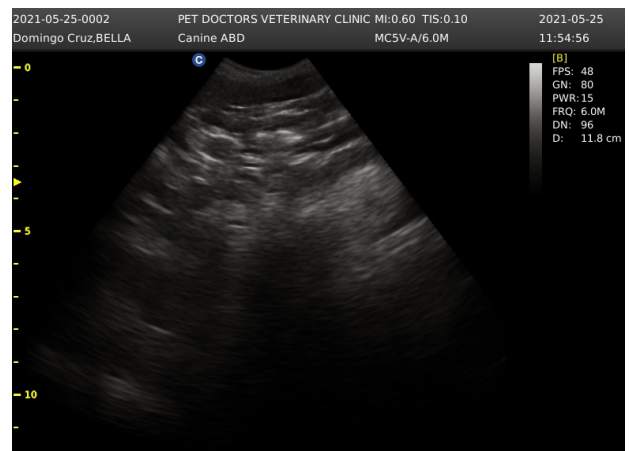
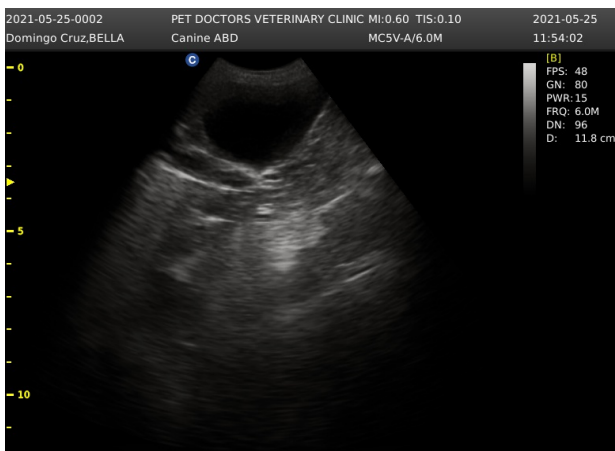
Weight

5.50 kg

BSA

0.32 m²

Ultrasound Image:



Description

No visible fetal sac/ fetal heartbeat

Tips

Doctor's signature(or stamp)

Date

This report is used for clinical reference only, Not used as prove material.