



PET DOCTORS VETERINARY CLINIC

Canine Report

Patient Name: Sarmiento, Ana, PEPPA

Age: 2

Sex: Female

Patient ID: 2021-05-04-0001

Diagnostic

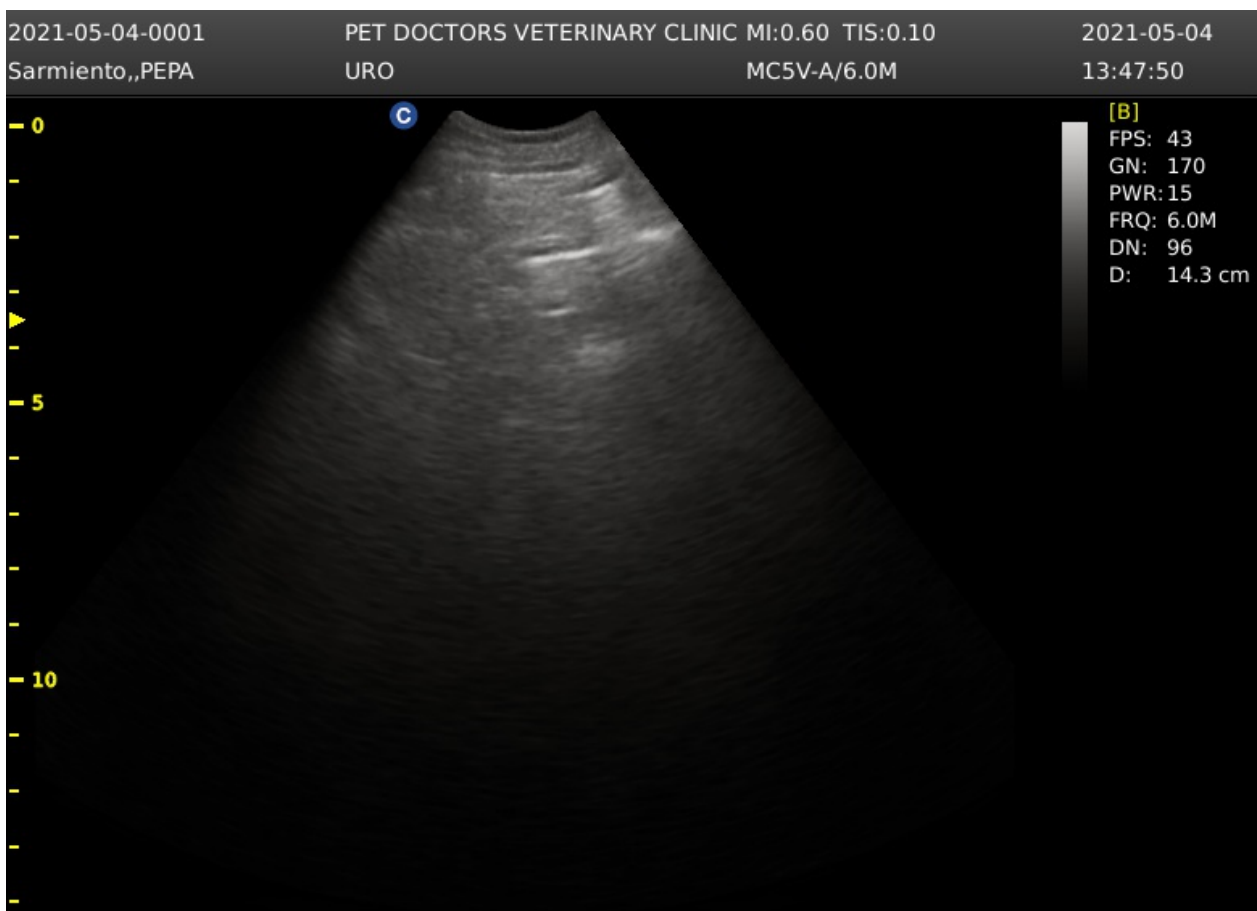
Weight

5.90 kg

BSA

0.33 m²

Ultrasound Image:



Description

No fetal sac/fetal heartbeat seen

Tips

Doctor's signature(or stamp)

Date

This report is used for clinical reference only, Not used as prove material.