



PET DOCTORS VETERINARY CLINIC

General Report

Patient Name: Titus Rafanan, Pinggo

Age: 0

Sex: Female

Patient ID: 2021-04-24-0002

Diagnostic

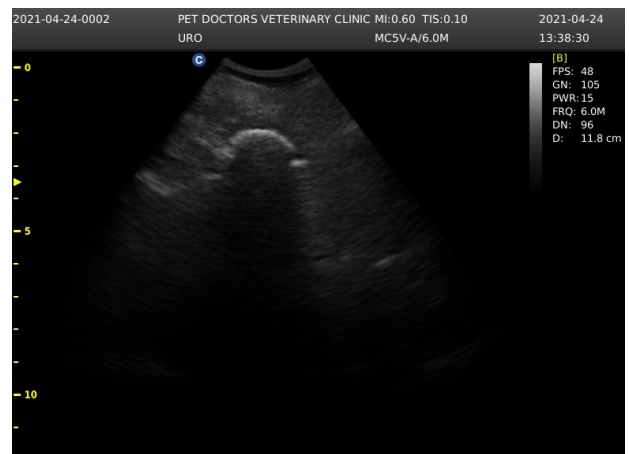
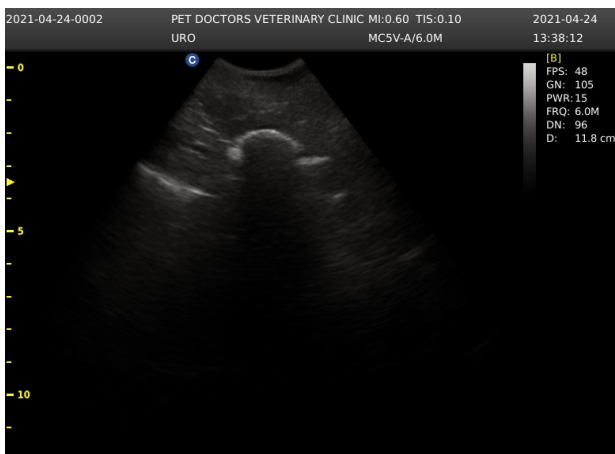
Weight

5.10 kg

BSA

0.30 m²

Ultrasound Image:



Tips

Doctor's signature(or stamp)

Date

This report is used for clinical reference only, Not used as prove material.