

Canine Report

Patient Name: Viray, Austria, Silver Gray

Age: 0

Sex: Female

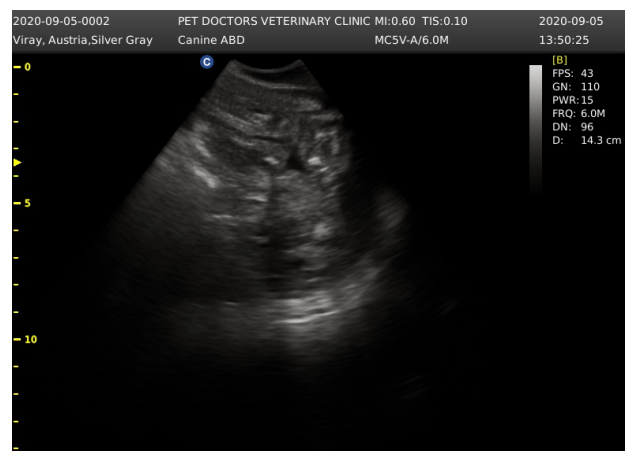
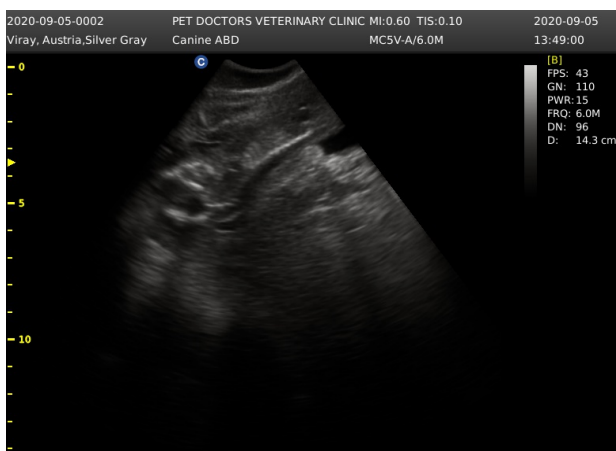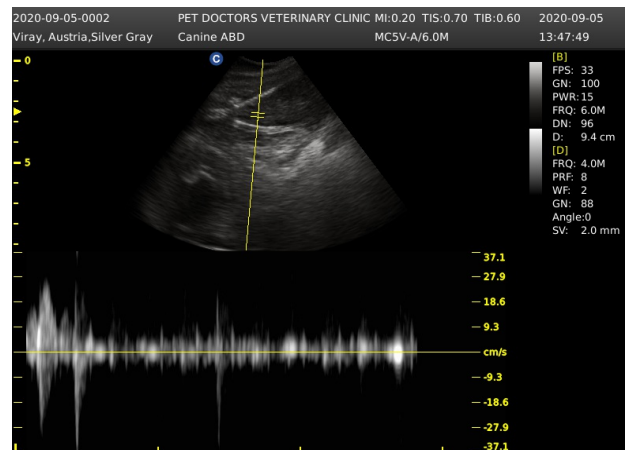
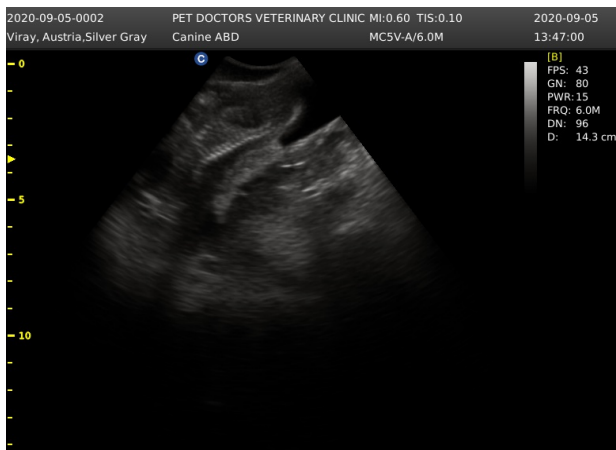Patient ID: 2020-09-05-0002

Diagnostic

+ Fetal heartbeat

Weight	6.40 kg	BD	2.29 cm Avg
BSA	0.35 m ²	BD_GA	6w4d
HD	2.07 cm Avg	BD_EDD	2020-09-24
HD_GA	7w2d	Average GA	6w6d
HD_EDD	2020-09-19	Average EDD	2020-09-22

Ultrasound Image:



Description

Tips

Doctor's signature(or stamp)

Date

This report is used for clinical reference only, Not used as prove material.