

# Pet Doctors Veterinary Supplies and Services

## Fecal Morphology Analysis Report

Pet Name: Blake  
 Gender: Male  
 Sample ID: 260605002  
 Fecal Color: Brown

Owner Name: Camille Porserio  
 Age: 4Y  
 Sample Type: Feces  
 Fecal Consistency: Formed, Soft

Species: Canine  
 Patient or Visit NO.:  
 Time Tested: 05/06/2026 13:28:36

Test	Result	Unit	Reference Range	Negative	Positive
<b>1. Parasite</b>					
1-1 Trichuris eggs (TRV#)	0	a	0-0		
1-2 Ascaris eggs (ALE#)	0	a	0-0		
1-3 Ancylostome eggs (ANE#)	0	a	0-0		
1-4 Cestode eggs (CEE#)	0	a	0-0		
1-5 Dipylidium eggs (DIP#)	0	a	0-0		
1-6 Spirometra eggs (SPI#)	0	a	0-0		
1-7 Trematode eggs (TRE#)	0	a	0-0		
1-8 Alaria eggs (ALA#)	0	a	0-0		
<b>2. Intestinal protozoa</b>					
2-1 Trichomonas (TRI#)	0	a	0-0		
2-2 Giardia (GIA#)	0	a	0-0		
2-3 Giardia trophozoites (GIAT#)	0	a	0-0		
2-4 Giardia cysts (GIAC#)	0	a	0-0		
2-5 Coccidia (COD#)	0	a	0-0		
<b>3. Germ</b>					
3-1 Coccus (COS#)	739	a/ug	241-1215		
3-2 Bacillus (BAC#)	8562	a/ug	850-23173		
3-3 Coccus/Bacillus ratio (C/B)	0.086	/	0.017-0.156		
3-4 Campylobacter (CAM#)	10.1	a/ug	0.0-50.0		
3-5 Bacillus spp (CLO#)	0.0	a/ug	0.0-60.0		
3-6 Helicobacteria (SS#)	1.6	a/ug	0.0-10.0		
3-7 Yeast (YEA#)	0.0	a/ug	0.0-250.0		
<b>4. Cell</b>					
4-1 Red blood cell (RBC#)	3330.5	↑ a/ug	0.0-5.0		
4-2 White blood cell (WBC#)	37.5	↑ a/ug	0.0-5.0		
4-3 Epithelial cells (EPC#)	30.8	↑ a/ug	0.0-20.0		
<b>5. Digestive function</b>					
5-1 Starch granule (STA#)	0.0	a/ug	0.0-15.0		
5-2 Lipid drop (LFAT#)	0.0	a/ug	0.0-2.0		
5-3 Plant fiber (PLA#)	1.8	a/ug	0.0-5.0		
5-4 Muscle fiber (AF#)	0.0	a/ug	0.0-10.0		

### Clinical Significance

RBC# **Elevated levels:** It is common in lower intestinal inflammation or intestinal bleeding.  
 WBC# **Elevated levels:** It is common in enteritis and tumors caused by bacteria, viruses, allergies and parasitic infections.  
 EPC# **Elevated levels:** It is suggested that intestinal injury is common in colitis.



Hospital Tel: +639171533903

Hospital Add: McArthur Highway, San Miguel, Calasiao, Pangasinan



# Pet Doctors Veterinary Supplies and Services

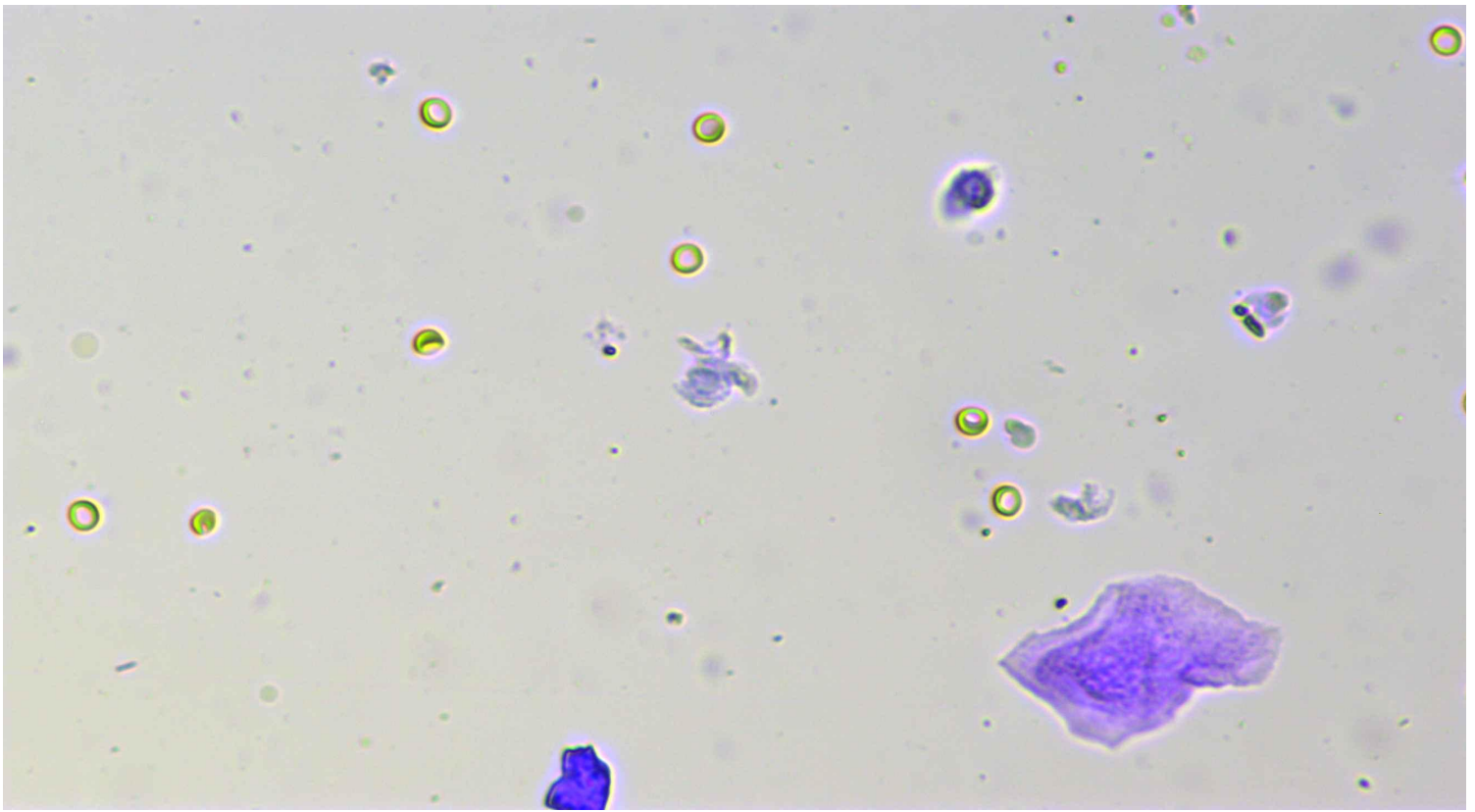
## Fecal Morphology Analysis Report


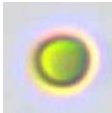




Pet Name: Blake  
 Gender: Male  
 Sample ID: 260605002


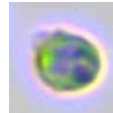
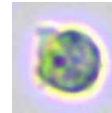
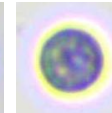
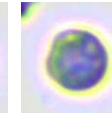
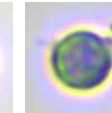
Owner Name: Camille Porserio  
 Age: 4Y  
 Sample Type: Feces

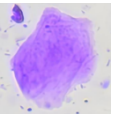
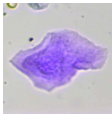
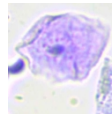
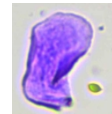
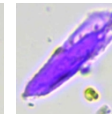
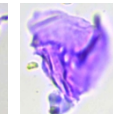
Species: Canine  
 Patient or Visit NO.:  
 Time Tested: 05/06/2026 13:28:36

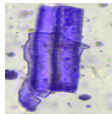
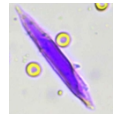
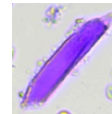
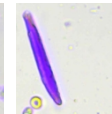
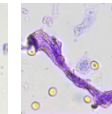
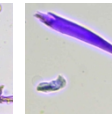
### Distribution Chart

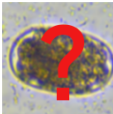
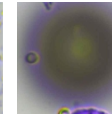



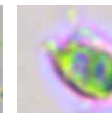
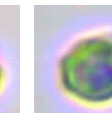

					
10um	Red blood cell(RBC#)				Concentration:3330.5 a/ug

					
12um	White blood cell(WBC#)				Concentration:37.5 a/ug

					
50um	Epithelial cells(EPC#)				Concentration:30.8 a/ug

					
75um	Plant fiber(PLA#)				Concentration:1.8 a/ug

					
40um	Suspected parasite(SPAR#)				Count:

					
50um	Suspected intestinal protozoa(SPRO#)				Count:

Veterinary Technician: not specified  
 Attending Veterinarian: Dr. Marian Grace Wanagen

Date Reported: 05/06/2026



**Hospital Tel: +639171533903**  
**Hospital Add: McArthur Highway, San Miguel, Calasiao, Pangasinan**



**This report is solely for the received sample and serves as a diagnostic reference for veterinarians.**



**Hospital Tel: +639171533903**

**Hospital Add: McArthur Highway, San Miguel, Calasiao, Pangasinan**

