

# Pet Doctors Veterinary Supplies and Services

## Blood Morphology Analysis Report

Pet Name: Leo

Owner Name:

Species: Feline

Gender: Male

Age: 4Y

Patient or Visit NO.:

Sample ID: 260420005

Sample Type: Blood

Time Tested: 20/04/2026 15:53:30

Test	Result	Unit	Reference Range	Low	Normal	High
<b>1. WBC</b>						
1-1WBC	15.77	10 <sup>9</sup> /L	3.26-19.00			
1-2Neu#	12.45	↑ 10 <sup>9</sup> /L	1.75-11.50			
1-3Nst#	0.19	10 <sup>9</sup> /L	0.00-1.00			
1-4Nsg#	12.26	↑ 10 <sup>9</sup> /L	2.10-11.00			
1-5Nsh#	0.00	10 <sup>9</sup> /L	0.00-0.50			
1-6Lym#	2.10	10 <sup>9</sup> /L	0.73-7.86			
1-7Mon#	0.79	10 <sup>9</sup> /L	0.07-1.79			
1-8Eos#	0.38	10 <sup>9</sup> /L	0.06-1.93			
1-9Bas#	0.05	10 <sup>9</sup> /L	0.00-0.15			
1-10Neu%	79.0	%	30.0-80.0			
1-11Nst/WBC%	1.2	%	0.0-12.0			
1-12Nsg%	77.8	↑ %	35.0-70.0			
1-13Nsh/WBC%	0.0	%	0.0-3.0			
1-14Lym%	13.3	%	7.0-50.0			
1-15Mon%	5.0	%	1.0-13.0			
1-16Eos%	2.4	%	0.5-11.0			
1-17Bas%	0.3	%	0.0-1.5			
1-18Nst/Neu%	1.5	%	0.0-16.0			
1-19Nsh/Neu%	0.0	%	0.0-5.0			
<b>2. RBC</b>						
2-1RBC	7.63	10 <sup>12</sup> /L	4.60-10.20			
2-2HGB	118	g/L	85-153			
2-3HCT	33.6	%	28.0-49.0			
2-4MCV	44.0	fL	35.0-58.0			
2-5MCH	15.4	pg	10.0-20.0			
2-6MCHC	350	g/L	250-430			
2-7RDW-CV	17.1	%	15.0-26.0			
2-8RDW-SD	28.6	fL	25.1-46.3			
2-9RET#	8.27	10 <sup>9</sup> /L	3.66-54.06			
2-10RET%	0.11	%	0.05-1.17			
2-11MCVr	43.4	fL	30.0-120.0			
2-12MCVr-CV	49.8	%	20.0-80.0			
2-13NRBC#	0.00	10 <sup>9</sup> /L	0.00-0.10			
2-14NRBC/WBC%	0.00	%	0.00-0.50			
2-15ETG#	0.02	10 <sup>12</sup> /L	0.00-0.15			
2-16ETG%	0.29	%	0.00-3.00			
2-17SPH#	9.26	10 <sup>9</sup> /L	0.00-150.00			
2-18SPH%	0.12	%	0.00-3.00			
2-19AGG#	0.00	10 <sup>9</sup> /L	0.00-0.50			
<b>3. PLT</b>						
3-1PLT	294	10 <sup>9</sup> /L	100-518			
3-2MPV	15.8	fL	9.9-16.3			
3-3PCT	0.464	%	0.090-0.700			
3-4PDW-CV	54.6	%	40.0-75.0			
3-5PDW-SD	13.4	fL	7.0-31.5			
3-6LPLT#	174	10 <sup>9</sup> /L	0-285			
3-7P-LCR	59.2	↑ %	9.0-55.0			



Hospital Tel: +639171533903

Hospital Add: McArthur Highway, San Miguel, Calasiao, Pangasinan



# Pet Doctors Veterinary Supplies and Services

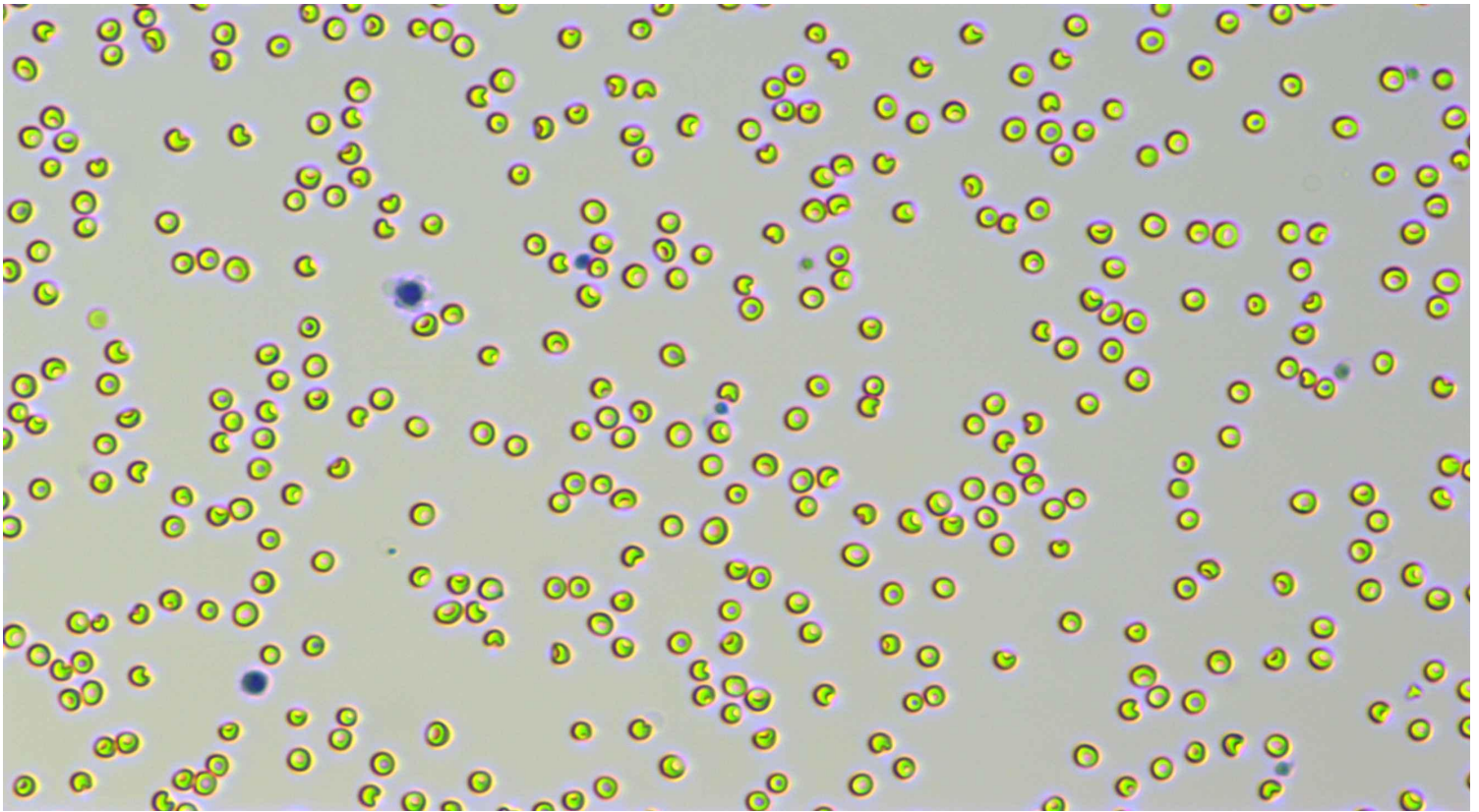
## Blood Morphology Analysis Report

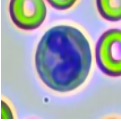
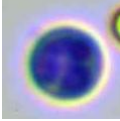
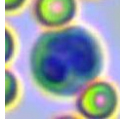
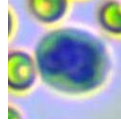
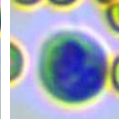
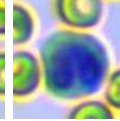
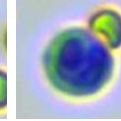
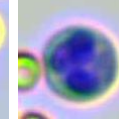
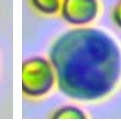
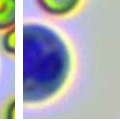
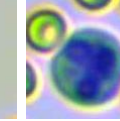
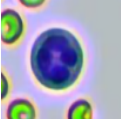
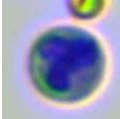
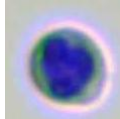
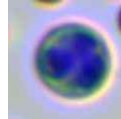
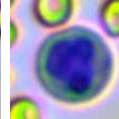
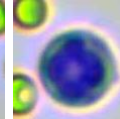
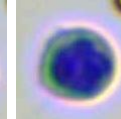
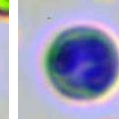
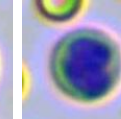
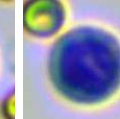
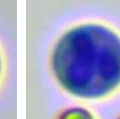
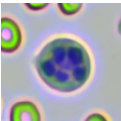



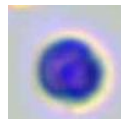
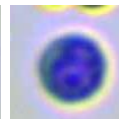


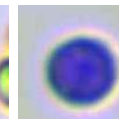
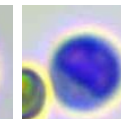
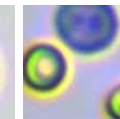

Pet Name: Leo  
 Gender: Male  
 Sample ID: 260420005

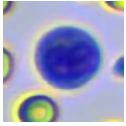
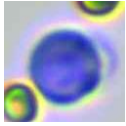
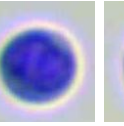
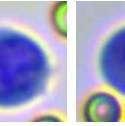
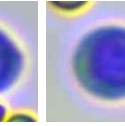
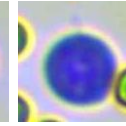
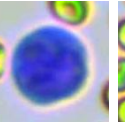
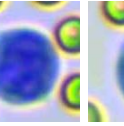
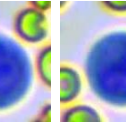

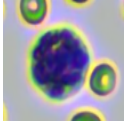
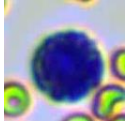
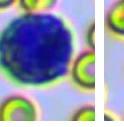

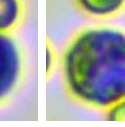

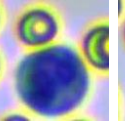
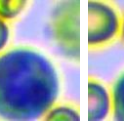
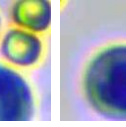

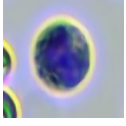






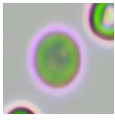






















Owner Name:  
 Age: 4Y  
 Sample Type: Blood

Species: Feline  
 Patient or Visit NO.:  
 Time Tested: 20/04/2026 15:53:30

### Distribution Chart



										
<p><b>Neutrophil stab granulocytes</b>      Count: 12.0      Concentration: <math>0.19 \times 10^9/L</math>      Percentage: 1.2 Nst#/WBC</p>										
										
<p><b>Neutrophil segmented granulocytes</b>      Count: 681.0      Concentration: <math>12.26 \times 10^9/L</math>      Percentage: 77.8 Nsg#/WBC</p>										
										
<p><b>Hypersegmented neutrophils</b>      Count:      Concentration:      Percentage:</p>										
										
<p><b>Lymphocytes</b>      Count: 114.0      Concentration: <math>2.10 \times 10^9/L</math>      Percentage: 13.3 Lym#/WBC</p>										

													
Monocytes	Count: 44.0	Concentration: $0.79 \times 10^9/L$				Percentage: 5.0 Mon#/WBC							
													
Eosinophils	Count: 21.0	Concentration: $0.38 \times 10^9/L$				Percentage: 2.4 Eos#/WBC							
	Count:	Concentration:				Percentage:							
Basophils													
													
Normocyte	Count: 121669.0	Concentration: $7.63 \times 10^{12}/L$			Percentage: 99.6 Normocyte#/RBC	Reticulocytes	Count: 13.0	Concentration: $8.27 \times 10^9/L$		Percentage: 0.11 RET#/RBC			
	Count:	Concentration:			Percentage:			Count: 363.0	Concentration: $0.02 \times 10^{12}/L$		Percentage: 0.29 ETG#/RBC		
Nucleated red blood cell							Erythrocyte ghost						
							Count:	Concentration:			Percentage:		
Spherocytes	Count: 141.0	Concentration: $9.26 \times 10^9/L$			Percentage: 0.12 SPH#/RBC		Agglutinated erythrocytes						
							Count:	Concentration:			Percentage:		
Normal platelets	Count: 6004.0	Concentration: $294 \times 10^9/L$			Percentage: 40.8 NPLT#/PLT		Large platelet						
	Count:	Concentration:			Percentage:								
Aggregate platelets													

### Clinical Significance

Neu#	<b>Elevated levels:</b> It is suggested that various acute infections, inflammations, stress reactions, some hematological diseases, toxic diseases, etc.
Nsg#	<b>Elevated levels:</b> It is suggested that various acute infections, inflammations, stress reactions, some hematological diseases, toxic diseases, etc.
P-LCR	<b>Elevated levels:</b> It is commonly seen in bone marrow reactive thrombocytopenia.

Veterinary Technician: Dr. Mikaela Rabino

Attending Veterinarian: Dr. Marian Grace Wanagen

Date Reported: 20/04/2026

**This report is solely for the received sample and serves as a diagnostic reference for veterinarians.**



Hospital Tel: +639171533903

Hospital Add: McArthur Highway, San Miguel, Calasiao, Pangasinan

