

# Pet Doctors Veterinary Supplies and Services

## Blood Morphology Analysis Report

Pet Name: Rice

Owner Name: Julius Cabatbat

Species: Canine

Gender: Female

Age: 3Y

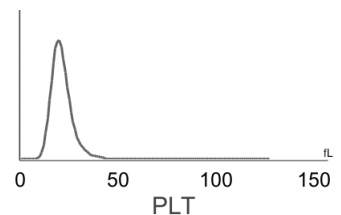
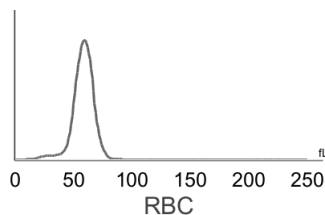
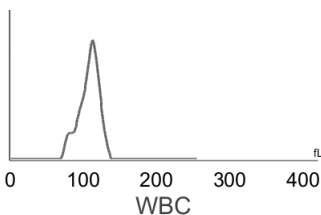
Patient or Visit NO.:

Sample ID: 260414008

Sample Type: Blood

Time Tested: 14/04/2026 20:12:03

Test	Result	Unit	Reference Range	Low	Normal	High
<b>1.WBC</b>						
1-1WBC	9.16	10 <sup>9</sup> /L	6.00-17.00			
1-2Neu#	6.95	10 <sup>9</sup> /L	3.62-12.30			
1-3Nst#	0.02	10 <sup>9</sup> /L	0.00-1.00			
1-4Nsg#	6.93	10 <sup>9</sup> /L	2.30-11.50			
1-5Nsh#	0.00	10 <sup>9</sup> /L	0.00-3.50			
1-6Lym#	0.99	10 <sup>9</sup> /L	0.83-4.91			
1-7Mon#	0.32	10 <sup>9</sup> /L	0.14-1.97			
1-8Eos#	0.90	10 <sup>9</sup> /L	0.04-1.62			
1-9Bas#	0.00	10 <sup>9</sup> /L	0.00-0.12			
1-10Neu%	75.9	%	50.0-81.0			
1-11Nst/WBC%	0.2	%	0.0-10.0			
1-12Nsg%	75.7	↑ %	48.0-70.0			
1-13Nsh/WBC%	0.0	%	0.0-15.5			
1-14Lym%	10.8	↓ %	12.0-33.0			
1-15Mon%	3.5	%	2.0-13.0			
1-16Eos%	9.8	%	0.5-10.0			
1-17Bas%	0.0	%	0.0-1.3			
1-18Nst/Neu%	0.3	%	0.0-22.0			
1-19Nsh/Neu%	0.0	%	0.0-20.0			
<b>2.RBC</b>						
2-1RBC	7.98	10 <sup>12</sup> /L	5.10-8.50			
2-2HGB	180	g/L	110-190			
2-3HCT	53.2	%	35.0-58.0			
2-4MCV	66.7	fL	55.0-83.0			
2-5MCH	22.5	pg	18.0-31.0			
2-6MCHC	338	g/L	260-430			
2-7RDW-CV	14.6	%	11.2-21.3			
2-8RDW-SD	37.0	fL	31.2-51.7			
2-9RET#	9.45	10 <sup>9</sup> /L	3.00-45.00			
2-10RET%	0.12	%	0.00-1.00			
2-11MCVr	47.2	fL	30.0-120.0			
2-12MCVr-CV	42.4	%	20.0-80.0			
2-13NRBC#	0.00	10 <sup>9</sup> /L	0.00-0.10			
2-14NRBC/WBC%	0.00	%	0.00-0.50			
2-15ETG#	0.03	10 <sup>12</sup> /L	0.00-0.10			
2-16ETG%	0.35	%	0.00-3.00			
2-17SPH#	6.67	10 <sup>9</sup> /L	0.00-150.00			
2-18SPH%	0.08	%	0.00-2.00			
2-19AGG#	0.00	10 <sup>9</sup> /L	0.00-0.50			
<b>3.PLT</b>						
3-1PLT	243	10 <sup>9</sup> /L	117-490			
3-2MPV	11.6	fL	8.4-14.1			
3-3PCT	0.282	%	0.090-0.580			
3-4PDW-CV	43.4	%	30.0-80.0			
3-5PDW-SD	8.8	fL	5.0-20.0			
3-6LPLT#	81	10 <sup>9</sup> /L	0-285			
3-7P-LCR	33.2	%	9.0-50.0			



Hospital Tel: +639171533903

Hospital Add: McArthur Highway, San Miguel, Calasiao, Pangasinan

